

# Progression of Cemental Tear: Report of Cases

A Author<sup>1\*</sup>, B Author<sup>1</sup>, C Author<sup>2</sup>, D Author<sup>1</sup>

<sup>1</sup>Department of ABC, University of ABS, Country

<sup>2</sup> Department of ABC, University of ABS, Country

## Introduction

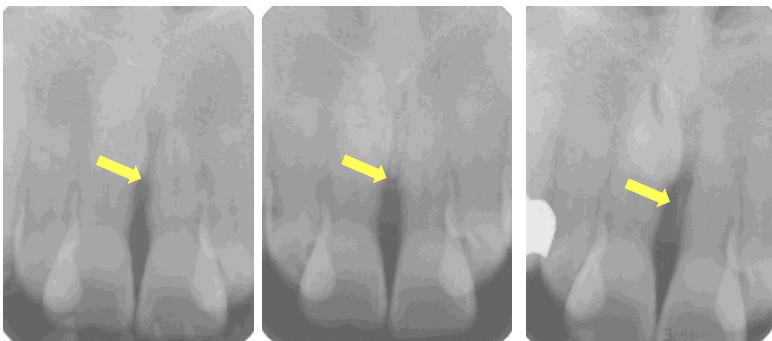
Cemental tear, so called cementodentinal tear, means a detachment of a fragment of cementum from a root surface and may include dentin issues. Biologic factors that lead to tearing of cementum are not known, but most frequently suspected causes are excessive occlusal force, previous trauma history, and aging. Cemental tear has been considered to be one of the potential factors of localized rapid periodontal breakdown because there is greater loss of attachment on the site of the tear in comparison with intact root surface.

### CASE 1

#### Patient's Profile

Age / Sex : 55Y / M

Site of cemental tear: #21

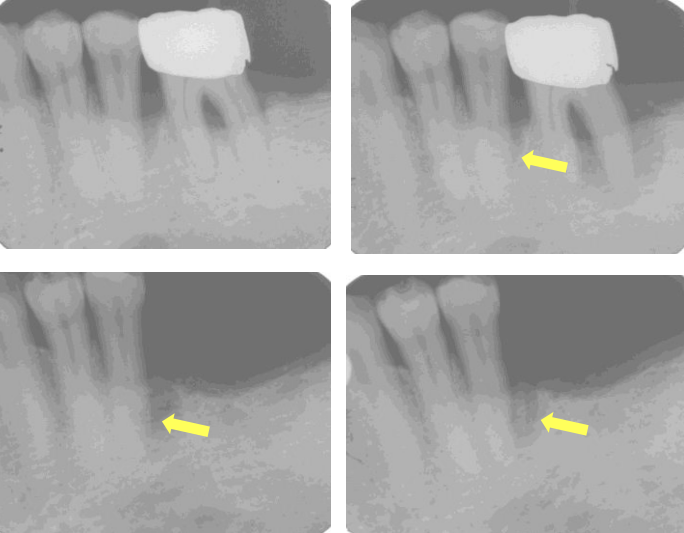


### CASE 2

#### Patient's Profile

Age / Sex : 55Y / M

Site of cemental tear: #35


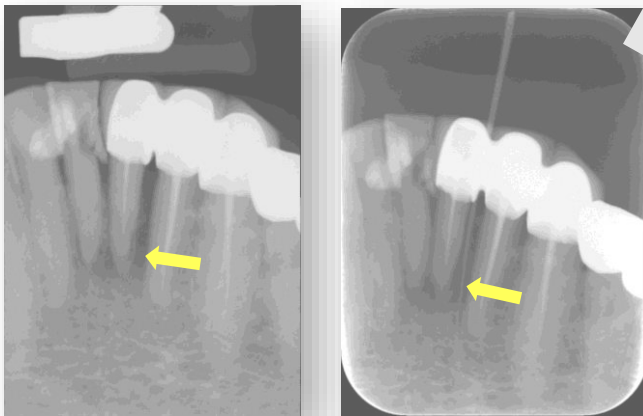


### CASE 3

#### Patient's Profile

Age / Sex : 78Y / F

Site of cemental tear: #1

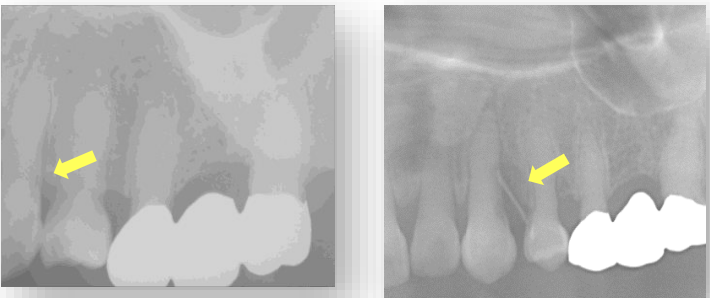
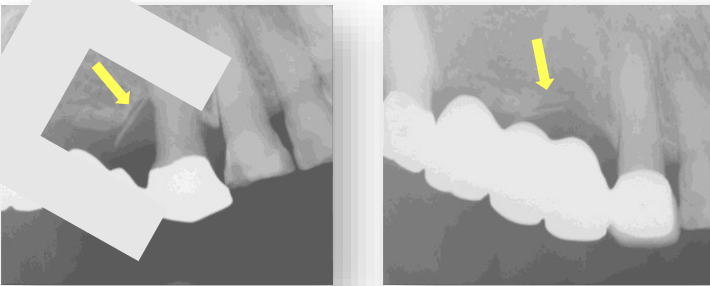


### CASE 4

#### Patient's Profile:

Age / Sex : 35Y / F

Multiple cemental tear  
(#14,23,34,35,43,44,45)  
Dentinogenesis imperfecta  
(type II)

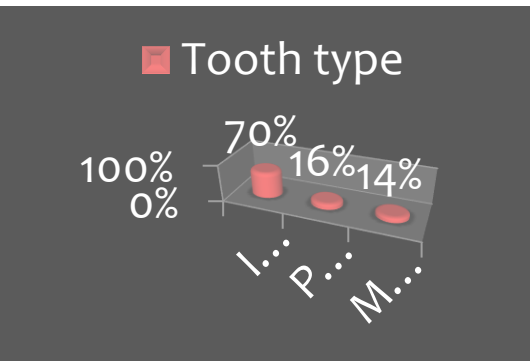




## Report of Cases

We report some cases of cemental tear of the patients visiting Gangneung-Wonju National University Dental Hospital (GWNUDH). They had lateral dental root surface that had prickly-like structure with suspicion of detachment of cementum from the root surface. Also there was severe alveolar bone loss sign on the root surface. This may be evidence of progressive separation of the fragment and progressive bone loss during the time. Also we surveyed patients visiting GWNUDH for 3 years for detection of cemental tear cases (lower bar graph).

## Conclusions

- We could suggest that cemental tear can be one of the causes of localized rapid alveolar bone loss.
- It is supposed that weak dentin like that in dentinogenesis imperfecta can cause cemental tear easily.
- We could know that cemental tear mainly occurred in incisors of male and older persons visiting GWNUDH.



Cemental tear cases (n=57) for 3 years,  
June, 2013 ~ June, 2016, in GWNUDH